



erbe
power your performance.



ENDO CUT® Q

Endoscopic polypectomy
and mucosal resection (EMR)
with ENDO CUT® Q

CONTENTS

INTRODUCTION	03
---------------------	-----------

TECHNOLOGY	04
ENDO CUT Q	
Cutting cycle	
Coagulation cycle	
Equipment	
User interface	
Experts mode	
Activation and activation signals	

IN PRACTICE	07
General parameter settings	
Operative techniques	
Preparation for polypectomy procedures and mucosal resection	
Polypectomy	
Endoscopic Mucosal Resection	

AVOIDING COMPLICATIONS	12
-------------------------------	-----------

RECOMMENDED SETTINGS	14
-----------------------------	-----------

LITERATURE	15
-------------------	-----------



Important information

While Erbe Elektromedizin GmbH has taken the greatest possible care in preparing this brochure and compiling the recommended settings, we cannot completely rule out errors. The information and data contained in the recommended settings cannot be used to justify any claims against Erbe Elektromedizin GmbH. In the event of compelling legal justification for a claim, liability shall be limited to intent and gross negligence.

Although the information on recommended settings, application sites, duration of application and the use of instruments is based on clinical experience, individual centers and physicians also favor settings other than those recommended here. This information is intended only as a guideline and must be evaluated by the surgeon for applicability. Depending on individual circumstances, it may be necessary to deviate from the information provided in this brochure.

Medicine is constantly subject to new developments based on research and clinical experience.

This is another reason why departing from the information provided here may be appropriate.



With the development of new endoscopic resection and hemostasis techniques, the removal of large polyps or other suspicious mucosal lesions is now possible without the need for open surgery.

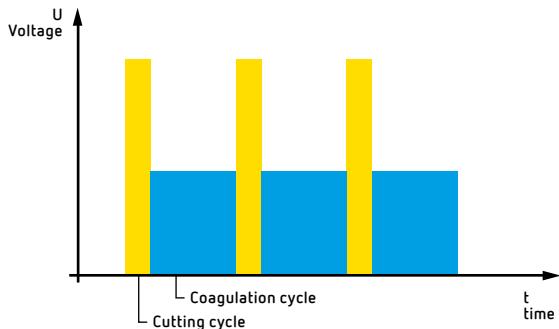
In endoscopic polypectomy and mucosectomy procedures, Erbe ENDO CUT has established itself as an accepted modality.

The ENDO CUT Q of the Erbe VIO system is a further development of the ENDO CUT offered by the "ERBOTOM ICC" 200 and 350 Model units which have been successfully used for more than 10 years.

This brochure is intended to help users understand the ENDO CUT Q and to use it correctly in their general clinical practice. The brochure targets both endoscopists and the entire endoscopy team.

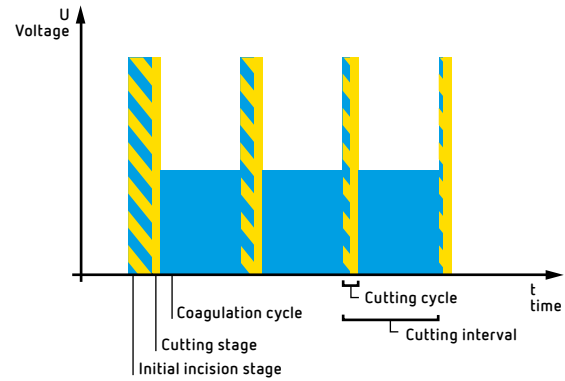
This brochure was created in close cooperation with experienced endoscopists working at different medical centers. Our particular thanks go to Prof. Schmitt in Neuperlach-Munich and Prof. Schulz in Berlin.

Technology



01

*Intermittent cutting mode ENDO CUT Q:
cutting cycle yellow, coagulation cycle blue*



02

*Cutting cycle with ENDO CUT Q: initial incision phase (yellow/blue),
cutting phase (yellow) and coagulation cycle (blue)*

ENDO CUT Q

The fractionated cutting mode ENDO CUT Q is distinguished by alternating cutting and coagulation cycles (Fig. 1). This facilitates controlled cutting with safe hemostasis throughout the entire dynamic cutting procedure while also supporting surgeons in carrying out their work.

Based on more than ten years of experience with ENDO CUT in endoscopy, voltage regulation in combination with electric arc detection (spark detection) have proven to be essential features with regard to the quality and reproducibility of the cutting effect.

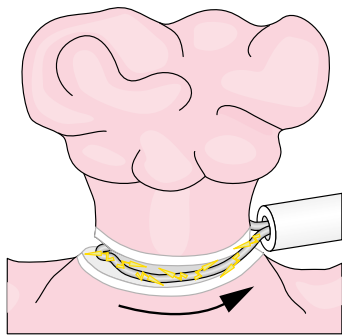
ENDO CUT Q is an additional enhancement that ensures safe and effective removal of large lesions, in particular large polyps.

ENDO CUT Q is a monopolar, high frequency (HF) surgical procedure where a cutting cycle based on two phases is followed by a coagulation cycle (Fig. 2):

Cutting cycle

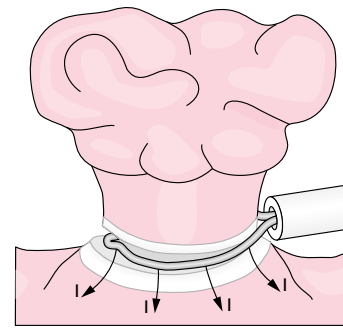
- a) Initial incision phase
- b) Cutting phase

Coagulation cycle



03

When cutting with a snare, small arcs (yellow) are created between the snare and the grasped tissue. The coagulation area in this illustration is gray/white. Arrow: direction of traction created by the snare.



04

Coagulation during cutting. The coagulated area (gray/white) is increased towards the base of the polyp. Arrows: Direction of current flow.

CUTTING CYCLE

a) Initial incision phase

A cutting cycle will always begin with a short initial incision stage of varying duration (Fig. 2). This serves to heat the tissue in the immediate vicinity of the electro-surgical snare endogenously within a few tenths of a second to $>100^{\circ}\text{C}$, leading to an initial coagulation (hemostasis) of the tissue prior to the actual cutting.

The duration of the initial cutting stage is mainly dependent on the diameter of the snare wire, diameter of the polyp, and the traction of the snare on the tissue it has grasped.

However, the initial cutting stage should be as short as possible to prevent deep coagulation at the base of the polyp. The quicker the cutting phase is arrived at, the more superficial the coagulated area will be. In the following illustrations the cutting cycle is simply depicted as a yellow bar.

b) Cutting phase

The beginning of the cutting phase is indicated by the formation of an electric arc between the tissue and the electro-surgical loop (Fig. 3). The electric arc develops at a high frequency voltage of $>200\text{V}$ as soon as the evaporation of tissue fluid results in a small gap between the electro-surgical loop and the tissue that has been gripped.

For a controlled and reproducible cutting result, it is beneficial if the development of the electric arc (spark) is detected automatically. This ensures that the cutting width is reproducible.

The cutting phase in ENDO CUT Q cutting mode is therefore dynamically and automatically regulated using spark detection.

COAGULATION CYCLE

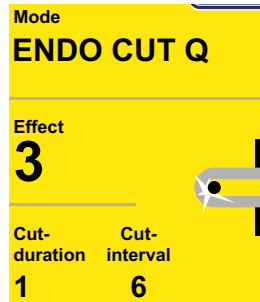
During the coagulation cycle the tissue is prepared for the next cutting cycle to ensure proper hemostasis prior to the subsequent cut.

The intensity of the coagulation, the so-called coagulation effect, can be modified with ENDO CUT Q with the help of four different settings.

The duration of the coagulation cycle can be finely adjusted using the Expert mode (cf. the chapter "Cutting interval" on page 8). It is important to remember that coagulation is significantly influenced by the effect setting and less by the duration of the coagulation process.

Depending on the chosen setting the coagulated area will increase towards the base of the polyp in the direction of the current flow (Fig. 4).

ENDO CUT Q
in the Expert mode



07

User interface
of the VIO system



06

GI workstation VIO 200 D



05

Equipment

ENDO CUT Q is a consequential further development of ENDO CUT, a well-known feature of the ICC units.

The Endo Cut Q mode, an optional upgrade, is available for the electro-surgical VIO units, some of which can also be equipped with it retroactively.

A complete system for endoscopic procedures can consist of the following (Fig. 5):

- Electro Surgical Unit (ESU), (Model VIO 200 D)
- Argon Plasma Coagulator (APC), (Model APC 2)
- Endoscopy Irrigation Pump (Model EIP 2)
- Integrated on the VIO Cart

USER INTERFACE

ENDO CUT Q is a cutting mode. This means that on the monitor or the user interface the ENDO CUT Q is displayed in the yellow field (Fig. 6).

Normally only the parameter "Effect" is displayed which allows the intensity of the coagulation to be adjusted during cutting.

EXPERT MODE

It is possible to activate the Expert mode to carry out individual adjustments (Fig. 7). If the Expert mode is activated (which should only be carried out by a trained Erbe representative) the parameters "Cutting duration" and "Cutting interval" will also be displayed on the interface and can also be adjusted.

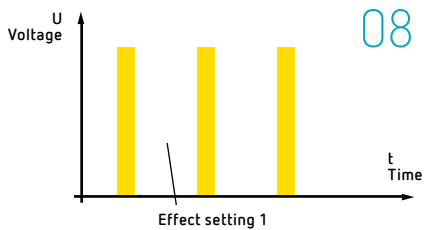
ACTIVATION AND ACTIVATION SIGNALS

ENDO CUT Q is activated by pressing the yellow foot pedal. The user is made aware of the activation by an acoustic signal, the activation signal. As soon as cutting effectively begins, a second acoustic signal will be heard, the cutting signal. The cutting signal serves as an acoustic control for the actual cutting.

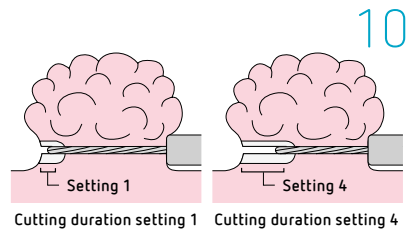
The yellow pedal of the foot switch should be pressed down until the polyp or the tissue grasped by the snare has been completely severed.

The cutting stage can be interrupted at any time by ceasing to activate the foot pedal.

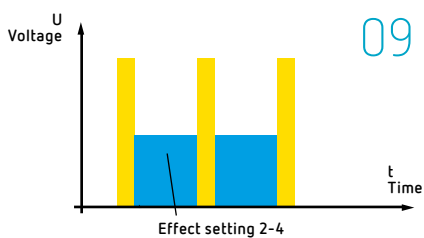
In practice



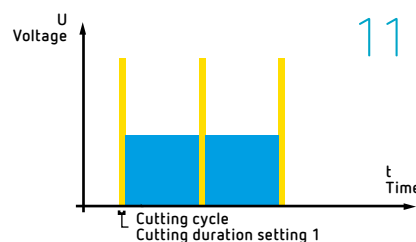
ENDO CUT Q with Setting 1: cutting current (yellow) without coagulation.



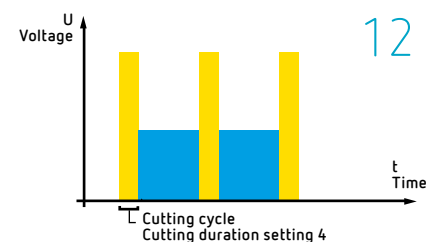
The cutting duration can be individually adjusted with ENDO CUT Q: left side = Setting 1, limited cut; right side = Setting 4, extensive cut.



The coagulation effect (blue) can be increased with ENDO CUT Q using the Effect Settings 2-4.



ENDO CUT Q with very brief cutting duration: Setting 1.



ENDO CUT Q with the longest cutting duration: Setting 4.

General parameter settings

EFFECT SETTINGS

Depending on the size, the shape and the location of the polyp it will be necessary to use different coagulation effects to ensure that the polypectomy is carried out with as little loss of blood as possible and with the lowest possible risk of perforation.

The intensity of the coagulation can be adjusted with the help of the parameter "Effect" using four different Effect settings.

Setting 1

With Setting 1 no coagulation is carried out between the individual cutting cycles (Fig. 8). This is a purely cutting current.

Setting 1 is suitable for the resection of polyps in high-risk areas where the walls are particularly thin, because if thermal damage occurs here due to too intense coagulation there is a risk of perforation.

Setting 2

With Setting 2 a very slight coagulation is carried out between the individual cutting cycles (Fig. 9).

Setting 3

With Setting 3 the coagulation between the individual cutting cycles is increased (Fig. 9).

Setting 4

With Setting 4 the coagulation between the individual cutting cycles is maximized. This setting is particularly suitable for applications which require extensive coagulation (Fig. 9).

CUTTING DURATION

Depending on the size, shape and location of polyps or other lesions it may be beneficial to vary the duration of cutting.

The extent of the cut is significantly dependent on the duration of cutting and can be adjusted using 4 different settings (only in the Expert mode, cf. page 6 for further details) (Fig. 10).

Setting 1:

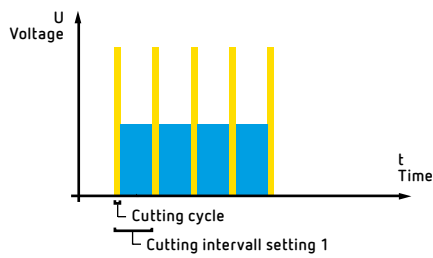
With Setting 1 the cutting duration is very brief, which also limits the extent of the cut (Fig. 11). Due to the very small cuts resection is very slow.

Settings 2-4:

With an upscale of the Setting Number the duration of the cut and thereby the speed of the cut increases.

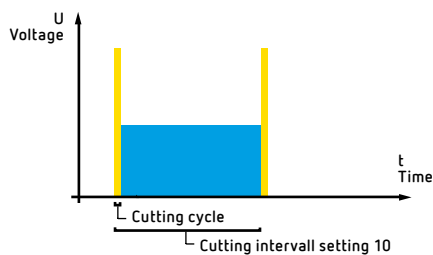
Settings 2 to 4 have a longer cutting duration each leading to a more extensive cut and therefore to a more rapid resection.

Praxis



13

ENDO CUT Q with cutting interval at Setting 1: the coagulation cycle (blue) with the smallest possible cutting interval.



14

ENDO CUT Q with cutting interval at Setting 10: maximum duration of a coagulation cycle (blue) with the greatest possible cutting interval.

CUTTING INTERVAL

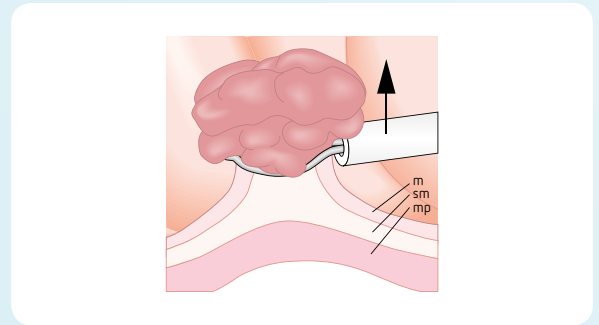
A cutting interval consists of a cutting and a coagulation cycle (Fig. 13). It is defined as the period of time between the beginning of one cutting cycle and the beginning of the next.

Adjustments of the duration of the cutting interval serve to control the fractionated cut. A short cutting interval favors a more rapid cut, longer cutting intervals result in a slower and more controlled resection.

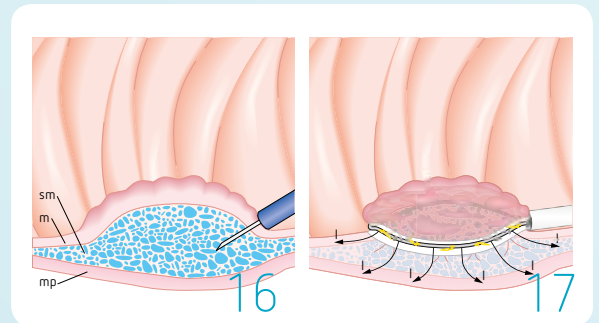
With the help of the parameter "Cutting interval" the duration of the coagulation cycle (in the Expert mode, cf. page 6) can be extended using 10 different settings. Please note that while the cutting interval will influence coagulation, the intensity of the coagulation is decisively influenced by the chosen effect setting (cf. page 7)!

Settings 1–10:

In Setting 1 there is only a very short break between the individual cutting impulses which leads to a rapid cut with limited coagulation (Fig. 13). The higher the setting, the longer the coagulation cycle and therefore the cutting interval (Fig. 14).

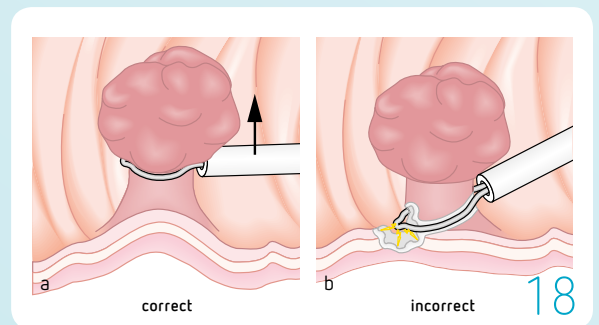


Elevating the polyp above the muscularis propria with the help of the snare prior to ablation.
m = mucosa, sm = submucosa, mp = muscularis propria.

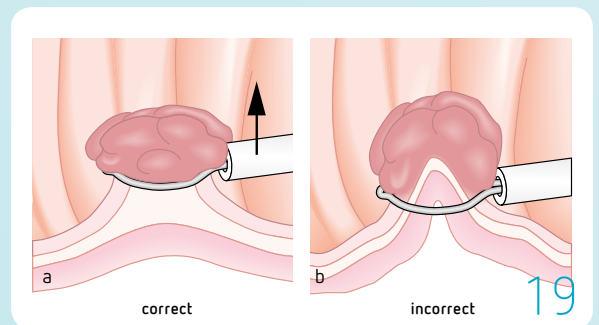


Submucosal (sm) injection. The distance between mucosa (m) and muscularis (mp) is increased after submucosal injection of liquid (blue).

With the submucosal injection the risk of selective thermal heating by the electrocautery current (black arrows) is reduced.



Positioning the snare. a) Elevating the polyp above the intestinal wall using the snare, b) wrongly positioned snare.



Controlling the amount of tissue grasped prior to carrying out the resection: a) the tissue has been grasped correctly and elevated using the snare in the direction of the arrow, b) in addition to the lesion a part of the intestinal wall was also grasped.

Operative techniques

Preparation for polypectomy procedures and mucosal resection

ELEVATING THE LESION

15

An important precondition for a successful and safe polypectomy or mucosal resection is elevation of the lesion (the polyp or mucosa) so that it stands out clearly from the muscularis propria (lifting sign) using the electrosurgical snare (Fig. 15) (or by means of a submucosal injection, see later). By increasing the distance to the muscularis propria the risk of thermal damage or perforation can be decreased. In addition, the fact that the lesion can be elevated (lifting sign) is an important diagnostic indicator (cannot be elevated = indicative of malignity with infiltrative growth).

SUBMUCOSAL INJECTION

Submucosal injection of lesions (for example with a physiological saline solution) offers several benefits. Firstly, this increases the distance between the tissue requiring excision and the muscularis propria (Figs. 16, 17). Due to the excellent electric conductivity and the heat conductance of the injected solution, the electric current applied will be distributed evenly within the saline cushion. This leads to a decrease in current density and to the creation of a thermal insulation layer. The risk of perforation is lessened.

Secondly, the lesion can usually be visualized better and grasped more easily after submucosal injection. This particularly applies to lesions which are located directly behind a fold or are not very elevated.

Furthermore, in addition to the purely mechanical pressure tamponade created by the submucosal injection it is also possible to initiate medicinal prophylaxis against bleeding using vasoconstrictive substances.

It is not imperative to carry out such preparations (as described above) prior to polypectomy procedures or mucosal resections and preparation will differ in different hospitals. The degree and type of preparation will vary depending on the experience and technique of the operating physician and on the clinical findings.

PLACING THE ELECTROSURGICAL SNARE

18,19

When positioning the electrosurgical snare it is important to take account of various aspects to avoid complications (bleeding, perforation):

- ☑ The snare should be placed around the lesion parallel to the intestinal wall, pressing lightly against the wall; the snare should then be closed slowly and lifted up parallel to the intestinal wall (Fig. 18 a).
- ☑ It is important to avoid one-sided tissue contact of the snare tip to the intestinal wall (Fig. 18 b).
- ☑ Visual control of the grasped tissue is important: if too much tissue has been grasped (including part of the wall) the snare should be opened and less tissue should be grasped (Fig. 19).
- ☑ It is important to avoid too much traction on the electrosurgical snare as this will lead to mechanical excision of the lesion without coagulation and therefore increase the risk of bleeding.

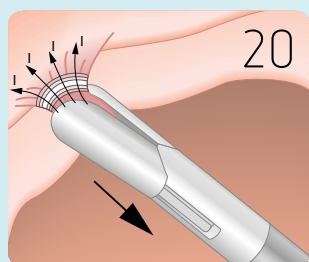
SPECIFIC FEATURES OF SNARE ELECTRODES

Single-strand (mono-filament) snares have a smaller area of contact with the tissue compared to multiple-strand (multi-filament, twisted) snares with the same diameter, which results in reduced coagulation.

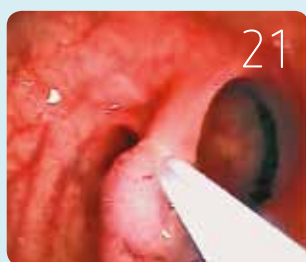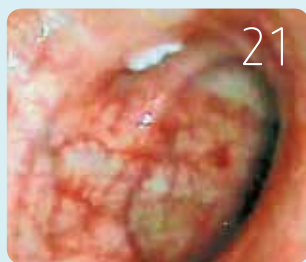The diameter of the wire influences the degree of coagulation. A smaller wire diameter will have a lower coagulation effect and a greater cutting effect.

Mono-filament snares are mechanically stiffer than multi-filament snares, which makes grasping the tissue easier.

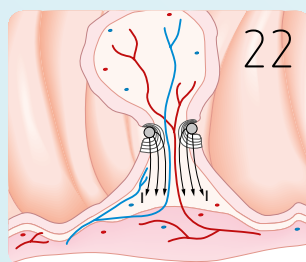
Polypectomy procedures at the upper margins



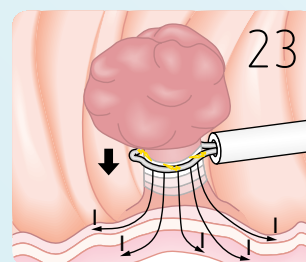
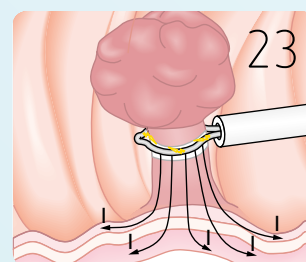
Ablation of small polyps with hot biopsy forceps. Before activating the coagulation current the polyp should be clearly elevated from the intestinal wall (large arrow). The current (I, arrows) is flowing in the direction of the polyp base.



a) stalked polyp in the colon after being grasped by the snare. b) slight coagulation at the base of the polyp after polypectomy (white area at 11 o'clock).



Cross-section of a stalked polyp. For the resection, the snare (orthograde, gray circles) must be placed firmly around the stalk of the polyp and continually tightened and repositioned in order to coagulate the inlying blood vessels.



Lengthwise shrinking of a stalked polyp.

PRE-COAGULATION

To reduce the risk of perforation pre-coagulation with FORCED COAG is recommended when treating stalked polyps or polyps > 10 mm (cf. recommended settings).

SMALL POLYPS

Polyps which are smaller than 5 mm may be removed by biopsy forceps. We recommend using the FORCED COAG mode when ablating polyps with hot biopsy forceps; it is also possible to harvest tissue for histological examination at the same time. In this procedure the polyp is grasped with the forceps and clearly elevated from the intestinal wall with a slight traction on the polyp. A coagulated area is created between the distal tip of the hot biopsy forceps and the ablation surface (Fig. 20).

STALKED POLYPS

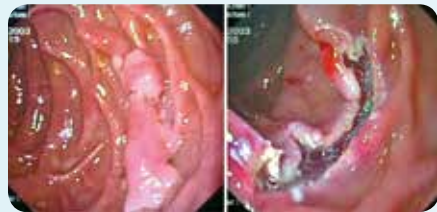Stalked (pedunculated) polyps between 5–15 mm in size (polyp head) can be ablated using either the FORCED COAG mode or ENDO CUT Q (Fig. 21). The polypectomy snare should be positioned close beneath the head of the polyp at a distance from the intestinal wall. As soon as coagulation becomes macroscopically visible at the stalk, the snare should be continually retightened and repositioned (Fig. 22). Too intensive coagulation in the direction of the polyp base increases the risk of perforation of the intestinal wall. Large stalked polyps (> 15 mm) are generally associated with a higher risk of bleeding. During the resection of large stalked polyps

with ENDO CUT Q we recommend carrying out bleeding prophylaxis either by submucosal injection, electrosurgical preconditioning, or by clipping. The high-frequency current will also cause the stalk of the polyp to shrink lengthwise (Fig. 23). It is therefore better not to plan the line of resection too close to the intestinal wall. With very large stalked polyps it is often difficult to differentiate between the proximal end of the stalk and the intestinal wall. In these cases we recommend carrying out the resection close to the head of the polyp.

SESSILE POLYPS

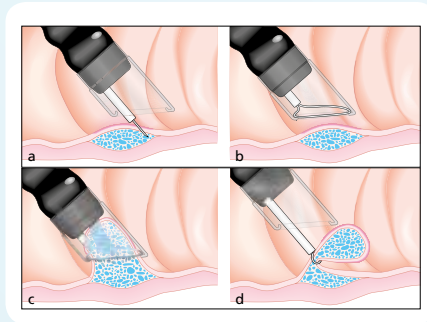
Submucosal injection is generally recommended when treating sessile polyps in order to ensure that the polyps are sufficiently separated from the intestinal wall. After the polypectomy snare has been properly positioned, the cutting mode ENDO CUT Q can be activated. During the cutting cycle the snare should be slowly tightened and repositioned under slight traction by an assistant. However, if the snare is too tight this could lead to an abrupt severing of the polyp (mechanical severance without sufficient coagulation). After the resection is completed, the resected material can be removed using any one of the commonly employed methods (snare, gripper, net, trap, etc.) – the type of removal will depend on the size of the resected specimen. The resection of large, sessile, broad-based polyps is usually carried out as a partial ablation using a piecemeal technique. Different methods, for example using a snare or a cap, are now used (please see the following chapter on EMR). With broad-based polyps it is not always possible to guarantee a complete resection of the polyp. Any polyp tissue at the base of the polyp still present after resectioning can be removed using Argon Plasma Coagulation (APC).

Endoscopic Mucosal Resection (EMR) at the upper margins



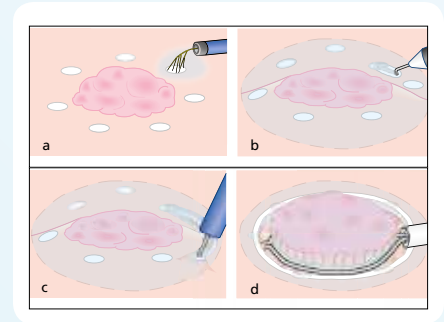
*a: Large adenoma in the duodenum.
b: Slight coagulation at the incision margins after snare resection.*

24



*EMR with a cap,
a) submucosal injection
b) Placing the snare and positioning the cap
c) Sucking in the mucosa
d) Resection outside the cap*

25



*EMR with a needle instrument,
a) marking the lesion
b) Opening up the mucosa after submucosal injection
c) Slitting open the mucosa with a needle electrode
d) Resection of the lesion with a snare.*

26

EMR WITH A SNARE

24

Prior to EMR with a snare we suggest using APC to mark the area in which there is a suspicion of polyp or carcinoma.

In EMR procedures with or without submucosal injection the lesion can either be removed in one piece "en bloc" (Fig. 24) or using a piecemeal technique.

After placing the snare around the lesion it is important to clearly elevate the lesion from its foundation (lifting sign), either using only the traction of the snare or by means of submucosal injection. This elevation is important diagnostically and as an important precondition for a successful and safe mucosal resection. The snare with the lesion is elevated in the direction of the intestinal lumen, away from the muscularis propria. The cutting process can then be initiated.

EMR USING A CAP

25

In EMR procedures with a cap (Figs. 25 a–d) with or without submucosal injection it may be useful to mark the size and the shape of the lesion using the electro-surgical snare (FORCED COAG mode) or by means of APC (Argon Plasma Coagulation). This will improve orientation, allowing the cap to be placed more precisely on the lesion, which will then be sucked into the cap. After the polyp has been firmly grasped by the snare the cutting process is initiated and the snare is slowly tightened simultaneously.

EMR WITH NEEDLE INSTRUMENTS

26

If the EMR is carried out using an "en bloc" technique (Figs. 26 a–d), it helps if the line of resection is marked using tiny points of coagulation prior to submucosal injection. We recommend using the mode FORCED COAG for such marking with needle instruments or Pulsed APC with an APC probe.

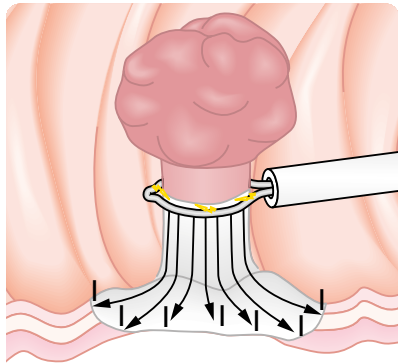
Subsequently, different needle instruments such as needle knives or hook knives together with ENDO CUT Q can be employed for the resection of the mucosa.

The lesion can then be resected either with needle instruments or using an electro-surgical snare.

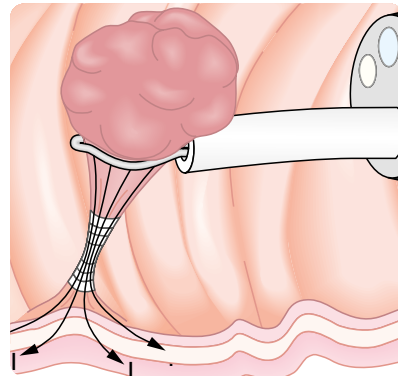
Due to the higher risk of perforation these EMR techniques (EMR with a cap or a needle instrument) should currently only be carried out in interventional centers by practitioners with sufficient experience.

Recommended settings for ENDO CUT Q for the different surgery techniques please find in the enclosed inset.

Avoiding complications



Thermal injury to the intestinal wall due to a too high energy output. The coagulated area is shown in gray/white).



The polyp was pulled too strongly into the lumen. This results in high current densities and coagulation (gray/white) at the point of constriction.

Complications

The two most common complications after a polypectomy or a mucosal resection are bleeding, which can either be spontaneous (primary) or delayed (secondary), and perforations.

It is important to differentiate between perforations which are due to a mechanical injury to the intestinal wall and those which are created by thermal necrosis.

The following chapter offers hints and pointers on how to use ENDO CUT Q to avoid complications.

A two-stage or hidden perforation can result from too great an energy output at the base of the polyp, during which a creeping necrotization of the intestinal wall may occur (Fig. 27).

This risk can be reduced by submucosal injection or elevation, particularly of broad-based lesions.

Resections should always be carried out under visual control so that the resection can be cut short if the coagulation effect at the base of the polyp is too great.

INTRAOPERATIVE BLEEDING DUE TO INSUFFICIENT HEMOSTASIS (PRIMARY BLEEDING)

Hemostasis during electrosurgical cutting depends essentially on two factors: on the chosen coagulation effect (effect setting) and on the mechanical traction by the snare on the polyp. If the polyp is constricted too much by the snare, then the polyp will be severed during the first cutting cycle. Because of insufficient coagulation this can lead to bleeding in both cases.

POSTOPERATIVE PERFORATION BY ELECTROSURGICAL CURRENT

If no cutting occurs despite activation of the foot switch, the operating physician should on no account continue to activate the foot switch. This could lead to a high energy output and subsequent thermal damage to the intestinal wall. Possible sources of the trouble can be wrongly set parameters or defective instruments.

COAGULATION OUTSIDE THE DIRECT CUTTING AREA

a) Constriction of the polyp

Too great an elevation of the polyp can result in extreme constriction at the base of the polyp.

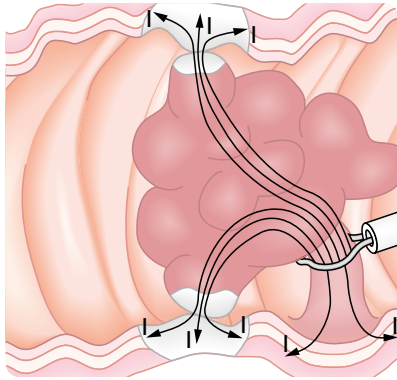
Such a constriction of tissue can lead to higher current densities which may result in a coagulation and potentially to an incision at some distance from the snare (Fig. 28).

b) Contact between the polyp and the intestinal wall

Contact between the polyp and the intestinal wall can lead to an uncontrolled flowing off the electric current. Together with high current densities at the points of contact this may result in a thermal injury of the intestinal wall (Fig. 29).

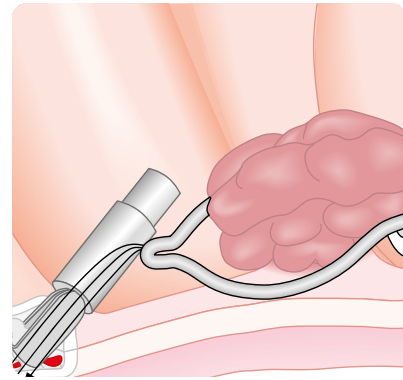
c) Unwanted contact of the snare and the intestinal wall

After the resection has been concluded the snare must be completely retracted into the insulated shaft so that if the foot switch is inadvertently activated during the removal of the snare no further coagulation effects will occur.



29

Thermal injury to the intestinal wall due to flowing off of the electrocautery current via the head of the polyp and the creation of high current densities (arrows).



30

Any contact between the electrocautery snare and a metal clip must be avoided, as the high current densities occurring at the clip can lead to thermal necrosis in the area around the clip.

CONTACT BETWEEN THE SNARE AND THE METAL CLIPS

If metal clips are used for hemostasis it is important to ensure that no electrocautery current can accidentally flow off via the metal clips during resection with the electrocautery snare (Fig. 30).

DEPRESSING THE FOOT SWITCH

If the pedal of the foot switch is depressed only briefly during resection, there will be no coagulation cycle between the cutting cycles. Only the cutting cycle will be activated. This can also lead to bleeding after resection. The yellow foot pedal must therefore be continually pressed throughout the procedure until the resection is complete.

Defective instruments/accessories

Only connecting cables without any defects should be used. Loose connecting plugs can lead to the creation of arcs at the connecting parts which could negatively affect the control of the operative procedure. The cutting stage might thus be prematurely interrupted, preventing any further cutting.

With polypectomy snares it is important to ensure that the snare can easily be opened via the snare shaft. On no account may defective polypectomy snares be used.

If closure of the snare is no longer possible during the polypectomy procedure, activation of the electrocautery generator must be immediately terminated, otherwise there is a risk of perforation of the intestinal wall.

FAULTY APPLICATION OF THE PATIENT PLATE

The area of contact between patient plate and skin must always be as large as possible. Any intraoperative lessening of the contact, for example if the patient plate comes off, can lead to thermal injury of the skin.

Improperly placed electrodes or reusable silicon patient plates with a higher impedance can negatively influence the effect of ENDO CUT Q.

We recommend using disposable dispersive electrodes which activate integral patient safety systems in the ESU such as NESSY (Neutral Electrode Safety System), REM, etc.

Note:

For more general information on electrocautery we recommend the brochure "Basic Principles of Electrocautery" from Erbe Elektromedizin GmbH.

Recommended settings

for ENDO CUT[®] Q

Polypectomy

Pre-coagulation

To reduce the risk of bleeding it is recommended to carry out a pre-coagulation when treating stalked polyps and polyps >10 mm:

FORCED COAG, Effect 2, 60 watts

Resection of polyps: polyps < 5 mm

Forceps biopsy

FORCED COAG, Effect 2, 60 watts

Resection of polyps: polyps > 5 mm

Mode

ENDO CUT Q

Effect

Setting 3

Cutting duration*

Setting 1

Cutting interval*

Setting 6

*Effect Setting 1: cecum, right colon
Effect Setting 2: duodenum, polyps >5 mm
Effect Setting 3: esophagus, stomach, polyps 5–15 mm
Effect Setting 4: rectum, stalked polyps, polyps >15 mm, large tumors*

Endoscopic mucosa resection (EMR)

EMR with snare

Marking the lesion:

Electrosurgical snare, needle instrument

FORCED COAG, Effect 2, 60 watts

Flexible APC probe

PULSED APC, Effect 1, 25 watts

Resection:

Mode

ENDO CUT Q

Effect

Setting 3

Cutting duration*

Setting 1

Cutting interval*

Setting 6

EMR with cap

Marking the lesion:

Electrosurgical snare, needle instrument

FORCED COAG, Effect 2, 60 watts

Flexible APC probe

PULSED APC, Effect 1, 25 watts

Resection with snare:

Mode

ENDO CUT Q

Effect

Setting 3

Cutting duration*

Setting 1

Cutting interval*

Setting 6

EMR with needle instrument

Marking the lesion:

Electrosurgical snare, needle instrument

FORCED COAG, Effect 2, 60 watts

Flexible APC probe

PULSED APC, Effect 1, 25 watts

Resection with needle:

Mode

ENDO CUT Q

Effect

Setting 2

Cutting duration*

Setting 4

Cutting interval*

Setting 3

** only in the expert mode*

Literature

- Ahmad NA, Kochman ML, Long WB, Furth EE, Ginsberg GG. Efficacy, safety, and clinical outcomes of endoscopic mucosal resection: a study of 1010 cases. *Gastrointestinal Endoscopy* 2002; 55(3):390-396.
- Binmoeller KF, Bohnacker S, Seifert H, Thonke F, Valdeyar H, Soehendra N. Endoscopic snare excision of "giant" colorectal polyps. *Gastrointest Endosc*. 1996; 43(3): 183-188.
- Brandimarte G. Endoscopic snare excision of large pedunculated colorectal polyps: A new, safe, and effective technique. *Endoscopy* 2001; 33(10):854-857.
- Brooker JC, Saunders BP, Shah SG, Williams CB. Endoscopic resection of large sessile colonic polyps by specialist and non-specialist endoscopists. *British Journal of Surgery* 2002; 89:1020-1024.
- Christie JP. Polypectomy or colectomy? Management of 106 consecutively encountered colorectal polyps. *Am Surg*. 1988;54(2):93-99.
- Classen M, Tytgat, GNJ, Lightdale CJ. *Gastroenterological Endoscopy*. Thieme-Verlag 2002.
- Deinlein P, Reulbach U, Stolte M, Vieth M, Risikofaktoren der lymphogenen Metastasierung von kolorektalen pT1-Karzinomen. *Pathologie* 2003;24:387-393.
- Di Giorgio P, De Luca L, Calcagno G, Rivellini G, Mandato M, De Luca B. Detachable snare versus epinephrine injection in the prevention of postpolypectomy bleeding: a randomized and controlled study. *Endoscopy* 2004; 36(10):860-863.
- Dobrowolski S, Dobosz M, Babicki A, Dymecki D, Hac S. Prophylactic submucosal saline-adrenaline injection in colonoscopic polypectomy: prospective randomized study. *Surgical Endoscopy* 2004; 18(6): 990-993.
- Dollhopf M, Heldwein W, Schmidtdorff G, Rösch T, Meining A, Schmitt W. Risk factors for perforation after polypectomy. Results of the Munich polypectomy study (MUPS) part 1. *Gastrointest Endosc* 2005; 55: AB99.
- Doniec JM, Lohnert MS, Schniewind B, Bokelmann F, Kremer B, Grimm H. Endoscopic removal of large colorectal polyps: prevention of unnecessary surgery? *Dis Colon Rectum*. 2003;46(3):340-348.
- Farin G. Möglichkeiten und Probleme der Standardisierung der Hochfrequenzleistung. In *Hochfrequenzdiathermie in der Endoskopie*; Springer-Verlag Berlin Heidelberg 1987.
- Fasoli R, Repaci G, Comin U, Minoli G, Italian Association of Hospital Gastroenterologists. A multi-center North Italian prospective survey on some quality parameters in lower gastrointestinal endoscopy. *Digestive and Liver Disease* 2002; 34(12):831-841.
- Frühmorgen P, Kriel L. Guidelines of the German Society of Digestive and Metabolic Diseases. Guidelines for endoscopic colorectal polypectomy with the sling. German Society of Digestive and Metabolic Diseases. *Z Gastroenterol*. 1998; 36(2):117-119.
- Kaneko E, Haradat H, Kasugi T, Sahita T. The result of a multicenter analysis from 1983-1992. *Gastroenterol. Endosc*. 1995;37:642-652.
- Garby JR, Suc B, Rotman N, Fourtainer G, Escat J. Multicentre study of surgical complications of colonoscopy. *British Journal of Surgery* 1996; 83:42-44.
- Giovannini M, Bories E, Presenti C, Moutardier V, Monges G, Danisi C, Lelong B, Delpero JR. Circumferential endoscopic mucosal resection in Barrett's esophagus with high-grade intraepithelial neoplasia or mucosal cancer. Preliminary results in 21 patients. *Endoscopy* 2004; 36(9):782-787.
- Giovannini M, Bernardini D, Moutardier V, Monges G, Houvenaeghel G, Seitz JF, Delpero JR. Endoscopic mucosal resection (EMR): results and prognostic factors in 21 patients. Preliminary results in 21 patients. *Endoscopy* 1999; 31(9):689-701.
- Greff M, Palazzo L, Ponchon TH, Canard JM; Council of The French Society of Gastrointestinal Endoscopy (S.F.E.D.). Guidelines of the French Society of Digestive Endoscopy: endoscopic mucosectomy. *Endoscopy* 2001; 33(2):187-190.
- Heldwein W, Dollhopf M, Schmidtdorff G, Rösch T, Meining A, Schmitt W. Risk factors for bleeding after polypectomy. Results of the Munich polypectomy study (MUPS) part 2. *Gastrointest Endosc* 2005; 55: AB99.
- Hurlstone DP, Sanders DS, Cross SS, Adam I, Shorthouse AJ, Brown S, Drew K, Lobo AJ. Colonoscopic resection of lateral spreading tumours: a prospective analysis of endoscopic mucosal resection. *Gut* 2004;53(9):1334-1339.
- Hsieh YH, Lin HJ, Tseng GY, Perng CL, Li AF, Chang FY, Lee SD. Is submucosal epinephrine injection necessary before polypectomy? A prospective, comparative study. *Hepatogastroenterology* 2001; 48(41): 1379-1382.
- Inoue H, Tani M, Nagai K, Kawano T, Takeshita K, Endo M, Iwai T. Treatment of esophageal and gastric tumors. *Endoscopy*. 1999; 31(1):47-55.
- Inoue H, Kawano T, Tani M, Takeshita K, Iwai T. Endoscopic mucosal resection using a cap: techniques for use and preventing perforation. *Can J Gastroenterol*. 1999; 13(6): 477-480.
- Kratzsch KH, Bosseckert H. Results of endoscopic polypectomy in the upper gastrointestinal tract-a multicenter study. *Deutsche Zeitschrift für Verdauungs- und Stoffwechselkrankheiten*.1984; 44(2):61-66.
- Löhnert MS, Wittmer A, Doniec JM. Endoscopic removal of large colorectal polyps. *Zentralbibliothek der Chirurgie* 2004; 129(4):291-295.
- Lux G, Semm K. *Hochfrequenzdiathermie in der Endoskopie*. Springer-Verlag Berlin Heidelberg, 1987 (Sonderdruck).
- Messmann H. *Lehratlas der Koloskopie*. Thieme Verlag 2004.
- Muehldorfer SM, Stolte M, Martus P, Hahn EG, Ell C. Diagnostic accuracy for forceps biopsy versus polypectomy for gastric polyps: a prospective multicenter study. *Gut* 2002; 50:465-470.
- Nivatvongs S. Complications in colonoscopic polypectomy. An experience with 1,555 polypectomies. *Dis Colon Rectum*. 1986;29(12): 825-830.
- Ono H, Kondo H, Gotoda T, Shirao K, Yamaguchi H, Saito D, Hosokawa K, Shimoda T, Yoshida S. Endoscopic mucosal resection for treatment of early gastric cancer. *Gut*. 2001; 48(2):225-229.
- Parra-Blanco A, Kaminaga N, Kojima T, Endo Y, Tajiri A, Fujita R. Colonoscopic polypectomy with cutting current: Is it safe? *Gastrointestinal Endoscopy* 2000; 51(6): 676-681.
- Parra-Blanco A, Kaminaga N, Kojima T, Endo Y, Uragami N, Okawa N, Hattori T, Takahashi H, Fujita R. Hemoclipping for postpolypectomy and postbiopsy colonic bleeding? *Gastrointestinal Endoscopy* 2000; 51(1):37-41.
- Ponchon T. Endoscopic mucosal resection. *J Clin Gastroenterol*. 2001; 32(1):6-10.
- Reed WP, Kilkenny JW, Dias CE, Wexner SD, SAGES EGD Outcomes Study Group. A prospective analysis of 3525 esophagogastroduodenoscopies performed by surgeons. *Surgical Endoscopy* 2004; 18:11-21.
- Rösch T, Sarbia M, Schumacher B, Deinert K, Frimberger E, Toerner T, Stolte M, Neuhaus H. Attempted endoscopic en bloc resection of mucosal and submucosal tumors using insulated-tip knives: a pilot series. *Endoscopy* 2004; 36(9):788-801.
- Schmitt W, Gospos J, Held T, Dollhopf M: Endoskopische Therapie der kolorektalen Neoplasie – neue Technik. *Dtsch med Wochenschr* 2000; 26:5250-5254.
- Schmitt W, Gospos J: Endoskopische Mukosektomie von breitbasigen großen Adenomen und T1-Karzinomen im Kolon. *Chir Gastroenterol* 2005; 21: 44-49
- Seitz U, Seewald S, Bohnacker S, Soehendra N. Advances in interventional gastrointestinal endoscopy in colon and rectum. *Int J Colorectal Dis*. 2003;18(1):12-18.
- Shim CS. Endoscopic mucosal resection: an overview of the value of different techniques. *Endoscopy*. 2001 Mar;33(3):271-275.
- Sieg A, Hachmoeller-Eisenbach U, Eisenbach T. Prospective evaluation of complications in outpatient GI endoscopy: a survey among German gastroenterologists. *Gastrointestinal Endoscopy* 2001; 53(6):620-627.
- Shim CS. Endoscopic mucosal resection: an overview of the value of different techniques. *Endoscopy* 2001; 33:271-275.
- Singh N, Harrison M, Rex DK. A survey of colonoscopic polypectomy practices among clinical gastroenterologists. *Gastrointestinal Endoscopy* 2004; 60(3):414-418.
- Takekoshi T, Baba Y, Ota H, Kato Y, Yanagisawa A, Takagi K, Noguchi Y. Endoscopic resection of early gastric carcinoma: results of a retrospective analysis of 308 cases. *Endoscopy* 1994; 26(4):352-358.
- Soehendra N, Binmoeller KF, Seifert H, Schreiber HW. *Praxis der therapeutischen Endoskopie*. Thieme Verlag 1997.
- Waye JD, Rex DK, Willima CB. *Colonoscopy*, 2003. Blackwell Publishing.
- Waye JD, Lewis BS, Frankel A, Geller SA. Small colon polyps. *Am J Gastroenterol* 1988; 83:120-122.
- Waye JD, Lewis BS, Yessayan S. Colonoscopy: a prospective report of complications. *Journal of Clinical Gastroenterology* 1992; 15(4):347-351.
- Waye JD, Kahn O, Auerbach ME. Complications of colonoscopy and flexible sigmoidoscopy. *Complications of Gastrointestinal Endoscopy* 1996; 6(2):343-377.



Erbe Elektromedizin GmbH
Waldhoernlestrasse 17
72072 Tuebingen
Germany

Phone +49 7071 755-0
Fax +49 7071 755-179
info@erbe-med.com
erbe-med.com